



# 中山醫學大學附設醫院

## 胃癌診療指引

本臨床指引參考國家衛生研究院胃癌臨床診療指引版本

胃癌多專科醫療團隊編修

2023/12/22 version14.0  
2022/12/23 version14.0  
2021/11/26 version13.0  
2020/12/11 version12.0  
2019/12/27 version11.0  
2018/11/23 version10.0  
2017/12/22 version9.0  
2016/12/16 version8.0  
2015/12/04 version7.0  
2014/12/26 version6.0  
2013/12/27 version5.0  
2012/09/28 version4.0  
2011/12/02 version3.0  
2010/12/31 Version2.0

癌症委員會主任委員	癌症委員會執行長	癌症中心主任	團隊負責人



## 修訂內容

頁數	原文	修訂/新增
此次無修訂		

# 目錄

一、 前言.....	1
二、 臨床症狀.....	2
三、 診斷方法.....	2
四、 胃癌轉移常見部位.....	3
五、 胃癌之分期.....	3
六、 胃癌診療指引.....	8
七、 癌症藥物治療原則.....	17
八、 放射線治療原則.....	29
九、 安寧緩和照護原則.....	30
十、 完治率定義.....	30
十一、 參考文獻.....	31



## 一、前言

日本、南美、東歐、部份中東地區及中國地區為高罹患率地區。胃腺癌依組織型態學分為兩大類：腸型和瀰漫型。腸型源自胃癌前驅病灶如萎縮性胃炎或腸型化生，較常見於男性及年老病人，而且是胃癌流行地區主要的組織型態，其主要來自環境的影響。瀰漫型胃癌並未有前驅病灶現象，在胃癌非盛行地區為主要的胃癌組織型態，較常見於女性及年輕病人。此外因消化性潰瘍、慢性胃炎、息肉、外傷等而做過部份胃切除之殘餘胃，經過一段時間(10年以上)，也有可能發生原發性殘胃癌。

胃癌病人有較高的幽門螺旋桿菌感染率，但幽門螺旋桿菌和胃癌的關係尚待進一步研究證實。大部份研究胃癌形成的學者認為食用生鮮蔬菜、水果及高纖維麵包較不易得胃癌。相反的，食用多量動物蛋白質及脂肪、高複雜性澱粉、高鹽醃漬之肉類或魚類和飲用水內含硝酸鹽，得胃癌的危險性增加。食用富含維生素A 和C 以及 $\beta$  胡蘿蔔素的食物得胃癌的危險性較低。



## 二、臨床症狀

由於胃癌病人沒有特定的臨床症狀，因此大部分病人被診斷出來時，已是晚期胃癌了。有些病人症狀類似消化性潰瘍，呈現出來的上腹疼痛，可被一般抗潰瘍藥物緩解；有些病人可能有體重減輕、食慾不振、疲倦、上腹部不適，甚至合併腹水，但這些無一為胃癌特定症狀。直至病況嚴重，引起吞嚥困難，持續性嘔吐等腸胃道阻塞症狀發生，才緊急就醫。根據醫學統計，胃癌細胞形成到臨床出現症狀其間，約長達20個月；而從有臨床症狀，到就醫做出正確的診斷，多半延誤6-8個月的時間；這段期間，若能提高警覺，儘早得到正確的診斷，多半會有很好的預後。

## 三、診斷方法

上消化道X光攝影和胃內視鏡檢查是胃癌診斷的兩大利器，這兩種檢查互有利弊。上消化道X光攝影比內視鏡檢查，更能看到胃整體的結構，對於病灶的範圍及黏膜下的腫瘤易顯現，且比較便宜，病人接受度高；但是上消化道X光攝影不能作切片檢查，無法得到組織學確證，則是其缺點。胃內視鏡診斷胃癌，其敏感性和特異性都很高，若再加上胃生體切片檢查，正確診斷率可高達95%以上。腹部超音波、內視鏡超音波及電腦斷層檢查，對於胃癌手術前之分期、侵犯程度及有無轉移跡象亦有幫助。



## 四、胃癌轉移常見部位

胃癌的轉移分為四大種類，局部侵犯、淋巴腺轉移、腹膜轉移及血液轉移、局部侵犯可侵犯到附近的器官，包括肝臟、胰臟、橫結腸、食道或大動脈，造成手術切除的困難或變成不可切除；淋巴腺的轉移可能是局部性，也可能是全身性的淋巴腺；腹膜轉移也就是一般所謂的癌性腹膜炎；血液轉移最常見的還是肝臟、肺臟、骨頭等。

## 五、胃癌之分期

胃腺癌侵犯之深度與淋巴腺轉移的機會與病人的預後關係密切。依據腫瘤之侵犯深度，而分為早期癌(early cancer)和進行性癌(advanced cancer)。早期癌僅侵犯胃壁之黏膜層(mucosa)或黏膜下層(submucosa)，根據日本內視鏡學會的分類標準，可分為三個基本型：第I型是指凸出型，具有表淺性明顯的隆起。第II型又分為IIA、IIB及IIC三種亞型，IIA只有些微的隆起者；IIB無任何隆起或陷凹；IIC是略有凹陷者。第III型是潰瘍型，但癌細胞僅侷限於潰瘍周邊黏膜。進行癌依肉眼外觀的形態分為四種基本類型：第I型是息肉型或凸出型；第II型是周圍具有隆起邊緣的潰瘍稱為凹陷型；第III型是潰瘍且其邊緣已有浸潤者；第IV型是廣泛性浸潤型，無明顯界限，向胃腔內凸出不明顯，黏膜可有潰瘍，胃壁增厚變硬，若擴及全胃時稱皮革胃。胃癌分期則是依據原始腫瘤大小T，局部淋巴腺轉移的有無N以及遠處轉移的與否M，分為stage0(原位癌)、I(又可分成IA、IB)、II、III(又可分成IIIA、IIIB)、IV五級。

**AJCC 8<sup>th</sup> T-N-M**

<b>Primary Tumor(T)</b>	
TX	Primary tumor cannot be assessed
T0	No evidence of primary tumor
Tis	Carcinoma in situ; intraepithelial tumor without invasion of the lamina propria,high grade dysplasia
T1	Tumor invades the lamina propria,muscularis mucosae, or submucosa
T1a	Tumor invades the lamina propria or muscularis mucosae
T1b	Tumor invades the submucosae
T2	Tumor invades muscularis propria
T3	Tumor penetrates subserosal connective tissue without invasion of visceral peritoneum or adjacent structures
T4	Tumor invades serosa (visceral peritoneum) or adjacent structures
T4a	Tumor invades serosa (visceral peritoneum)
T4b	Tumor invades adjacent structures/organs

<b>Regional Lymph Nodes(N)</b>	
NX	Regional lymph nodes cannot be assessed
N0	No regional lymph node metastasis
N1	Metastasis in 1-2 regional lymph nodes
N2	Metastasis in 3-6 regional lymph nodes
N3	Metastasis in seven or more regional lymph nodes
N3a	Metastasis in 7-15 regional lymph nodes
N3b	Metastasis in 16 or more regional lymph nodes



Distant Metastasis(M)	
M0	No distant metastasis
M1	Distant metastasis

cT-N-M Stage Grouping							
Stage 0	Tis	N0	M0	Stage II B	T3	N0	M0
Stage I	T1	N0	M0		T4a	N0	M0
Stage I	T2	N0	M0	Stage III	T3	N1	M0
Stage II A	T1	N1	M0		T3	N2	M0
	T1	N2	M0		T3	N3	M0
	T1	N3	M0		T4a	N1	M0
Stage II A	T2	N1	M0		T4a	N2	M0
	T2	N2	M0		T4a	N3	M0
	T2	N3	M0	Stage IV A	T4b	Any N	M0
				Stage IV B	Any T	Any N	M1





pT-N-M		Stage	Grouping				
Stage 0	Tis	N0	M0				
Stage I A	T1	N0	M0				
Stage I B	T1	N1	M0	StageIIIB	T1	N3b	M0
	T2	N0	M0		T2	N3b	M0
Stage II A	T1	N2	M0		T3	N3a	M0
	T2	N1	M0		T4a	N3a	M0
Stage II B	T3	N0	M0		T4b	N1	M0
	T1	N3a	M0		T4b	N2	M0
	T2	N2	M0	StageIIIC	T3	N3b	M0
	T3	N1	M0		T4a	N3b	M0
StageIIIA	T4a	N0	M0		T4b	N3a	M0
	T2	N3a	M0		T4b	N3b	M0
	T3	N2	M0	StageIV	Any T	Any N	M1
	T4a	N1	M0				



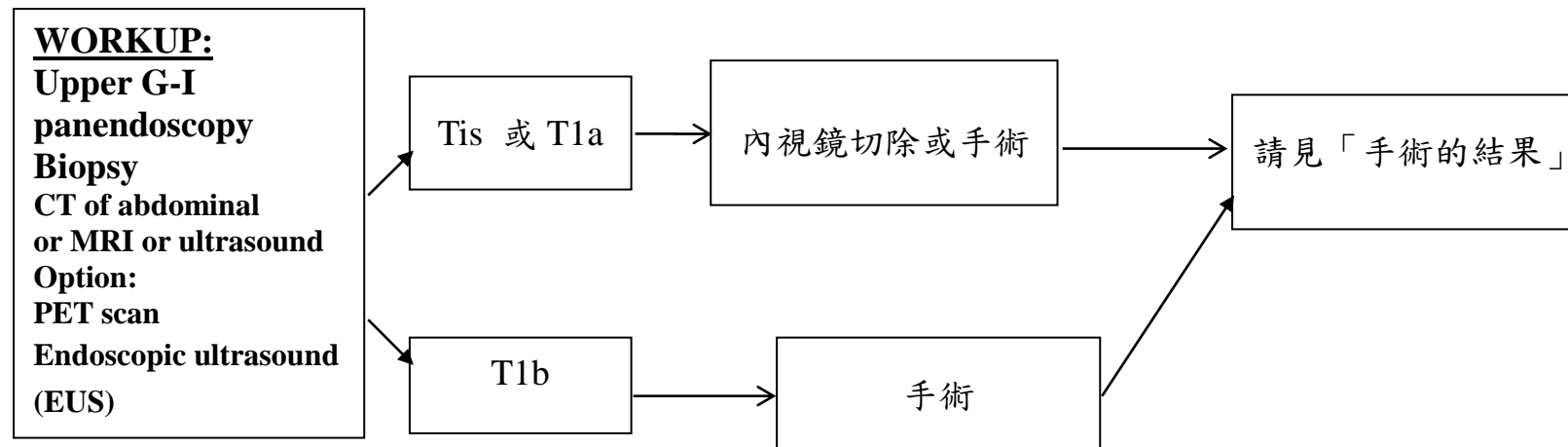
## Post Neoadjuvant Therapy

	ypT-N-M			Stage	Grouping		
Stage I	T1	N0	M0	Stage III	T4a	N1	M0
Stage I	T2	N0	M0		T3	N2	M0
Stage I	T1	N1	M0		T2	N3	M0
Stage II	T3	N0	M0		T4b	N0	M0
	T2	N1	M0		T4b	N1	M0
	T1	N2	M0		T4a	N2	M0
	T4a	N0	M0		T3	N3	M0
	T3	N1	M0		T4b	N2	M0
	T2	N2	M0		T4b	N3	M0
	T1	N3	M0		T4a	N3	M0
				Stage IV	Any T	Any N	M1

Histologic Grade(G)	
GX	Grade cannot be assessed
G1	Well differentiated
G2	Moderately differentiated
G3	Poorly differentiated
G4	Undifferentiated

## 六、胃癌之診療指引

早期胃癌 (cTis, cT1 and cN0M0)



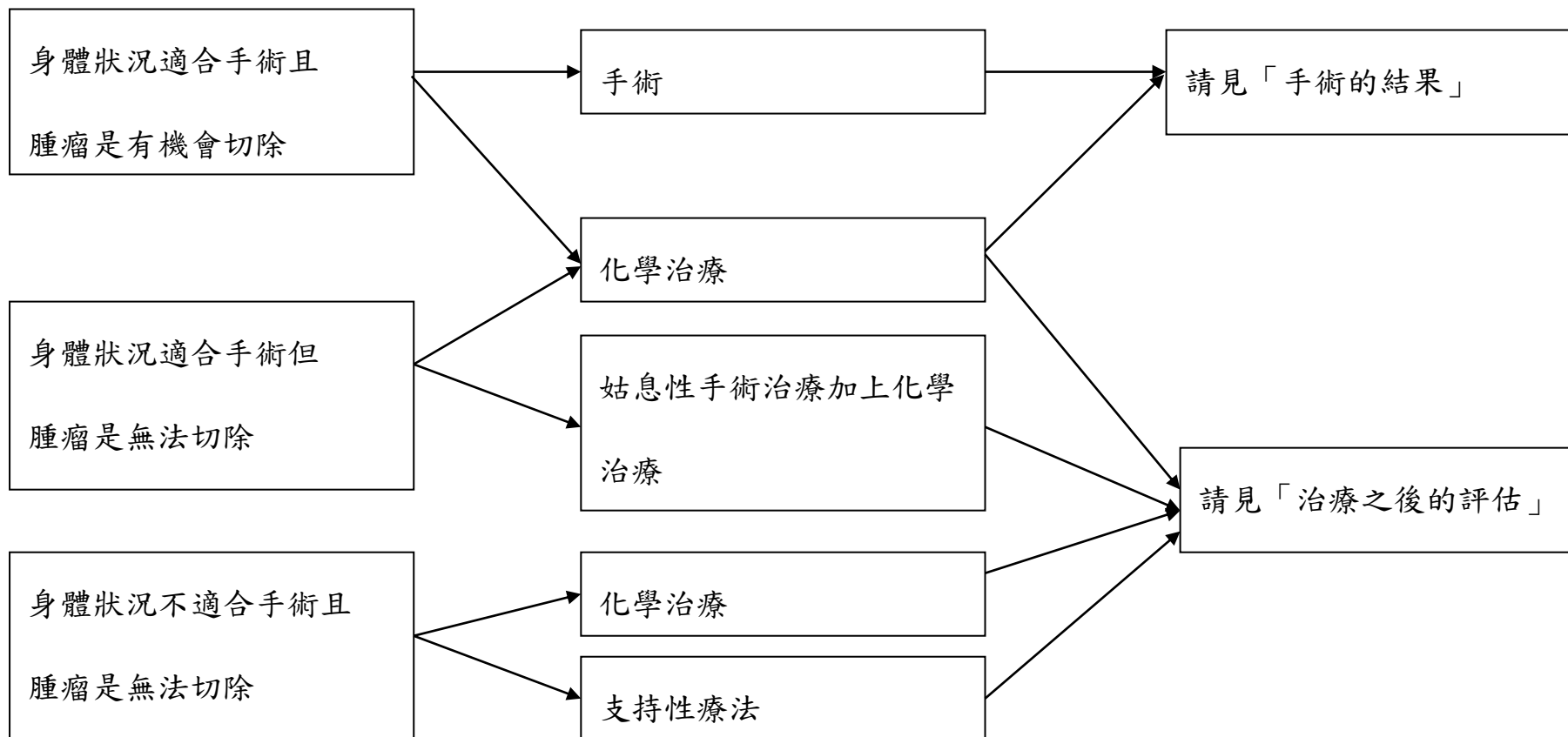
Tis: 原位癌

T1a: 原位癌浸潤至黏膜下固有層

T1b: 原位癌浸潤至黏膜下層

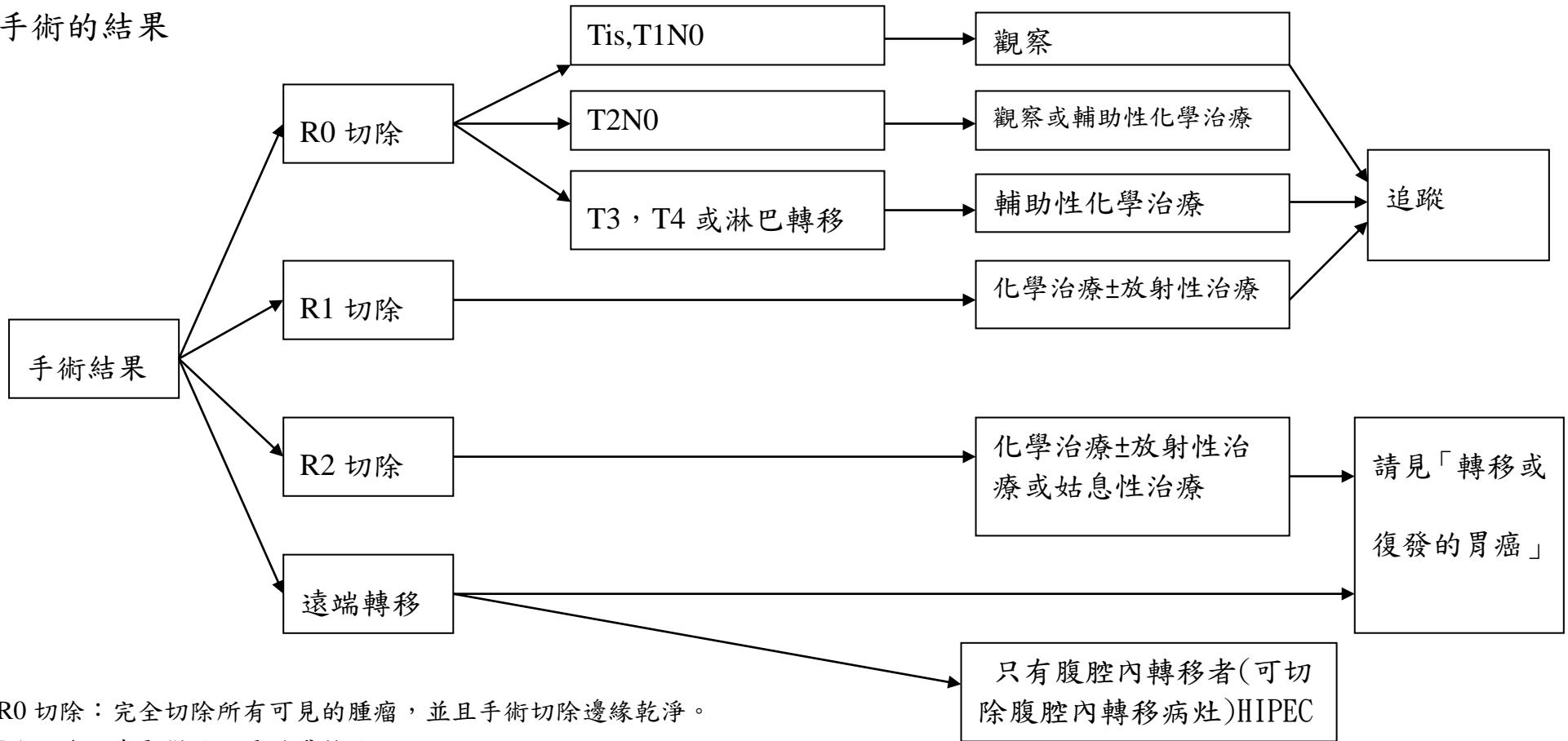


局部進行性胃癌(cT2-4N0-3M0)





手術的結果

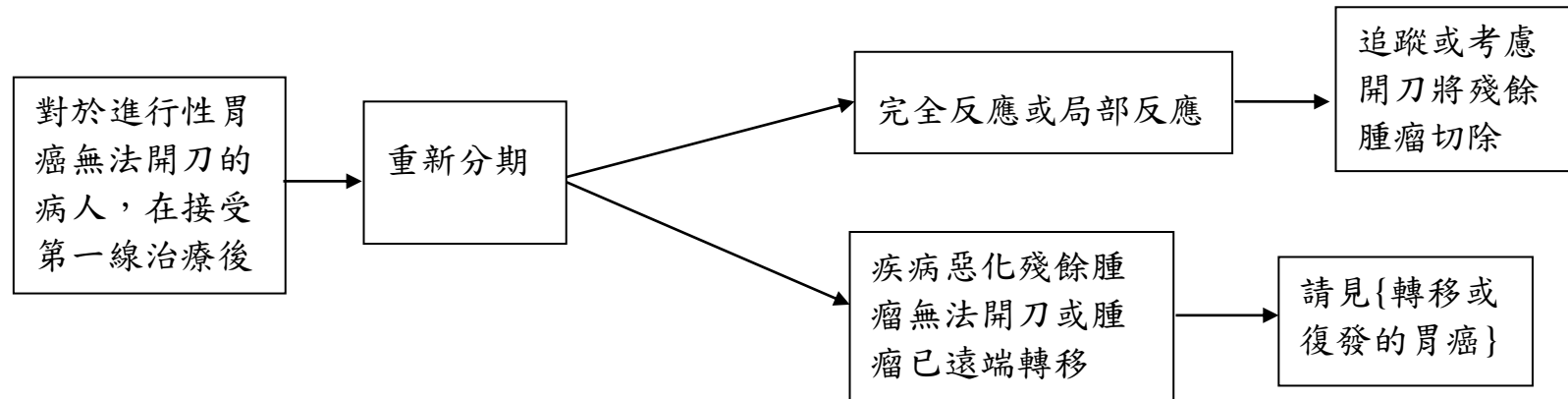


R0 切除：完全切除所有可見的腫瘤，並且手術切除邊緣乾淨。

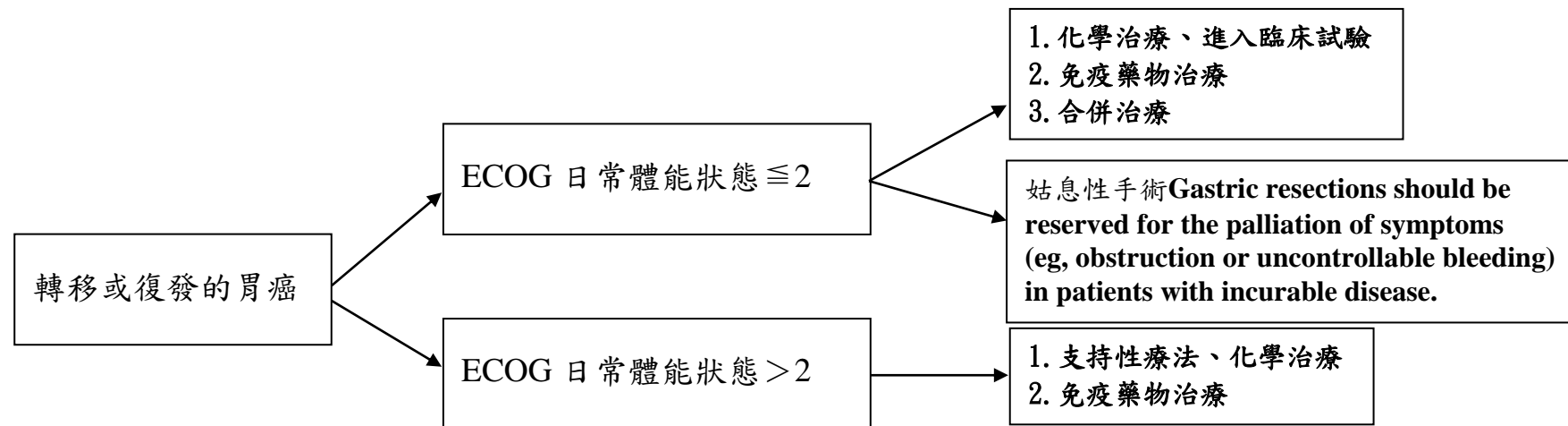
R1 切除：有顯微就可見的殘餘病灶

R2 切除：有肉眼可見的殘餘病灶

## Initial Unresetable GC



## 轉移或復發的胃癌(M1)



分數 ECOG

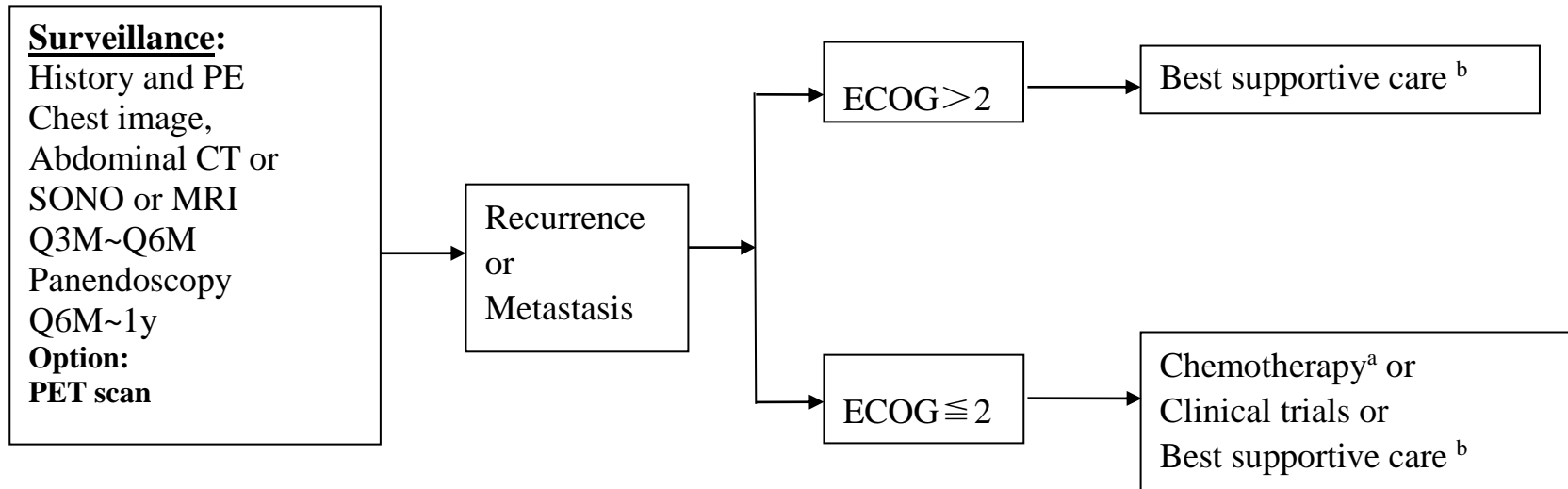
0 無症狀

1 有症狀，但是可以正常活動，對生活無影響

2 可以照顧自己但無法工作，躺在床上的時間  $< 50\%$  的工作時間3 躺在床上的時間  $> 50\%$  的工作時間

4 長期臥病在床

5 死亡

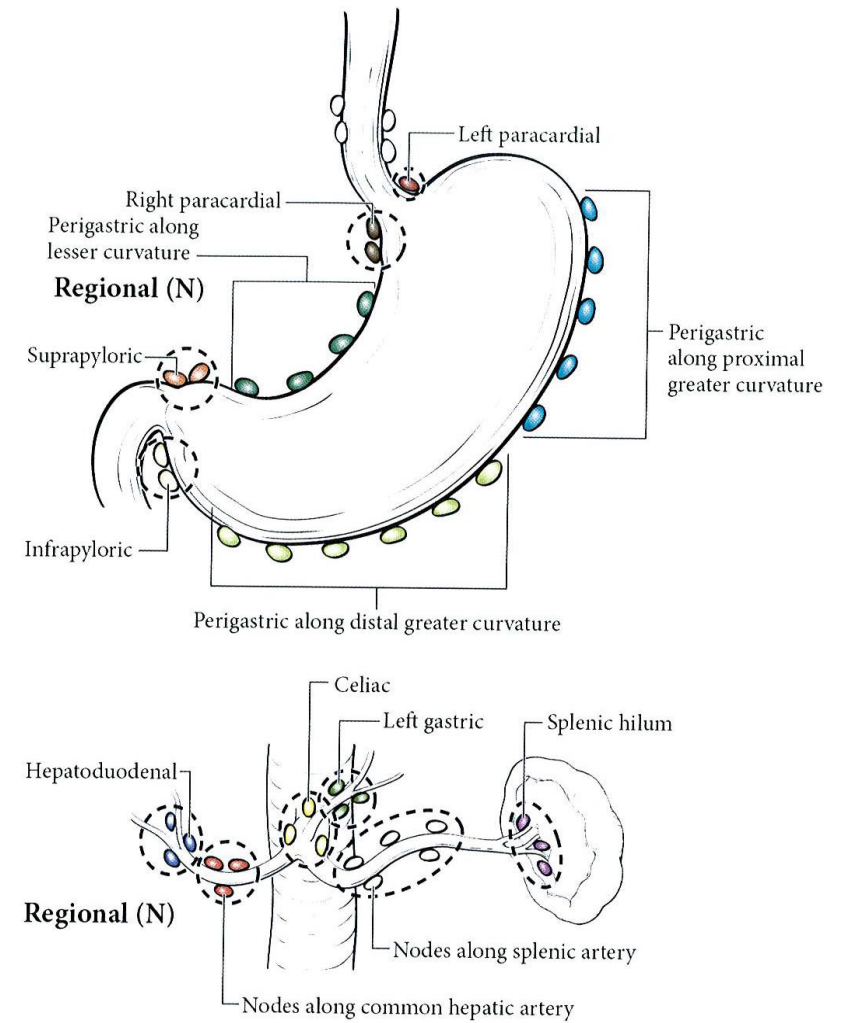
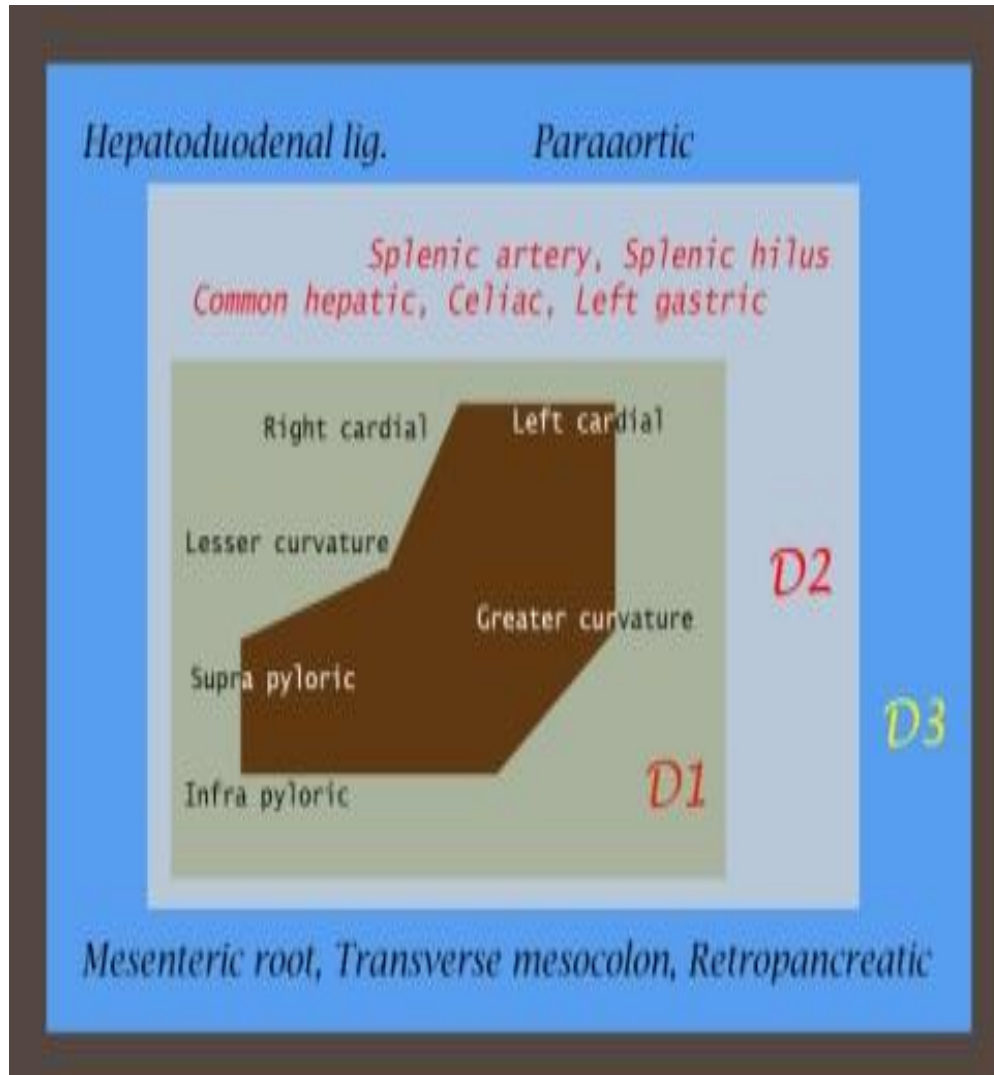


CCRT <sup>a</sup> is follow INT 0116 study. Not reserved for poor PS : Performance ECOG ≤ 2; age ≤ 70 y/o (but not contraindication if performance status is good); normal renal and liver function, Hb ≥ 10g/dl, ANC ≥ 2000/mm<sup>3</sup>, PLR ≥ 100000/mm<sup>3</sup>

Best supportive care <sup>b</sup>: (1) obstruction: palliative resection, intestinal bypass, stent; (2) pain: medications, R/T;

(3) bleeding: surgery, R/T; (4) nutrition

(3) bleeding: surgery, R/T; (4) nutrition





**Anatomical definitions of lymph node stations**

<b>Nr.</b>	<b>Definition</b>
1	Right paracardial LNs, including those along the first branch of the ascending limb of the left gastric artery
2	Left paracardial LNs including those along the esophagocardiac branch of the left subphrenic artery
3a	Lesser curvature LNs along the branches of the left gastric artery
3b	Lesser curvature LNs along the 2nd branch and distal part of the right gastric artery
4sa	Left greater curvature LNs along the short gastric arteries (perigastric area)
4sb	Left greater curvature LNs along the left gastroepiploic artery (perigastric area)
4d	Rt. greater curvature LNs along the 2nd branch and distal part of the right gastroepiploic artery
5	Suprapyloric LNs along the 1st branch and proximal part of the right gastric artery
6	Infrapyloric LNs along the first branch and proximal part of the right gastroepiploic artery down to the confluence of the right gastroepiploic vein and the anterior superior pancreaticoduodenal vein
7	LNs along the trunk of left gastric artery between its root and the origin of its ascending branch
8a	Anterosuperior LNs along the common hepatic artery
8p	Posterior LNs along the common hepatic artery
9	Coeliac artery
10	Splenic hilar LNs including those adjacent to the splenic artery distal to the pancreatic tail, and those on the roots of the short gastric arteries and those along the left gastroepiploic artery proximal to its 1st gastric branch
11p	Proximal splenic artery LNs from its origin to halfway between its origin and the pancreatic tail end
11d	Distal splenic artery LNs from halfway between its origin and the pancreatic tail end to the end of the pancreatic tail
12a	Hepatoduodenal ligament LNs along the proper hepatic artery, in the caudal half between the confluence of the right and left hepatic ducts and the upper border of the pancreas
11p	Proximal splenic artery LNs from its origin to halfway between its origin and the pancreatic tail end



11d	Distal splenic artery LNs from halfway between its origin and the pancreatic tail end to the end of the pancreatic tail
12a	Hepatoduodenal ligament LNs along the proper hepatic artery, in the caudal half between the confluence of the right and left hepatic ducts and the upper border of the pancreas
12b	Hepatoduodenal ligament LNs along the bile duct, in the caudal half between the confluence of the right and left hepatic ducts and the upper border of the pancreas
12p	Hepatoduodenal ligament LNs along the portal vein in the caudal half between the confluence of the right and left hepatic ducts and the upper border of the pancreas
13	LNs on the posterior surface of the pancreatic head cranial to the duodenal papilla
14v	LNs along the superior mesenteric vein
15	LNs along the middle colic vessels
16a1	Para-aortic LNs in the diaphragmatic aortic hiatus
16a2	Para-aortic LNs between the upper margin of the origin of the celiac artery and the lower border of the left renal vein
16b1	Para-aortic LNs between the lower border of the left renal vein and the upper border of the origin of the inferior mesenteric artery
16b2	Para-aortic LNs between the upper border of the origin of the inferior mesenteric artery and the aortic bifurcation
17	LNs on the anterior surface of the pancreatic head beneath the pancreatic sheath
18	LNs along the inferior border of the pancreatic body
19	Infradiaphragmatic LNs predominantly along the subphrenic artery
20	Paraesophageal LNs in the diaphragmatic esophageal hiatus
110	Paraesophageal LNs in the lower thorax
111	Supradiaphragmatic LNs separate from the esophagus
112	Posterior mediastinal LNs separate from the esophagus and the esophageal hiatus

***Distant Nodal Groups.*** Involvement of other (nonregional) intra-abdominal lymph nodes, such as the retropancreatic, pancreaticoduodenal, peripancreatic, superior mesenteric, middle colic, para-aortic, or retroperitoneal nodes, translates into a patient having metastatic disease (M1).

	N0	N1	N2	N3
Tis	EMR 或 ESD			IV 擴大手術 姑息手術 化學療法 放射線療法 緩和醫療
T1 (M) >2.0cm	IA EMR <i>a</i> 縮小手術 * <i>a</i>	IB 縮小手術 * <i>b</i> SRSG <i>b</i>	II SRSG <i>b</i>	
T1 (SM)	縮小手術 * <i>a</i> 縮小手術 * <i>b</i>			
T2	IB SRSG <i>b</i>	II SRSG <i>b</i>	IIIA SRSG <i>b</i>	
T3	II SRSG <i>b</i>	IIIA SRSG <i>b</i>	IIIB SRSG <i>b</i> 擴大手術-廓清	
	Optional 術後輔助化學 療法術前化學 療法	Optional 擴大手術-廓清 術後輔助化學療法 術前化學療法	Optional 擴大手術-廓清 術後輔助化學療法 術前化學療法	
T4	IIIA 擴大手術-合 切	IIIB 擴大手術-合切		
H1, P1, CY1, M1				

EMR 【Endoscopy mucosa resection】：分化型、<2.0cm陷凹型、UL（-）

\*縮小手術：<2/3胃切除、bursectomy(-)、omentectomy(-)

a：D1+ #7. #8a      b：D1+ #7. #8a. #9

SRSG <sup>b</sup>：定型手術Standard radical subtotal gastrectomy 【>2/3胃切除、D2】

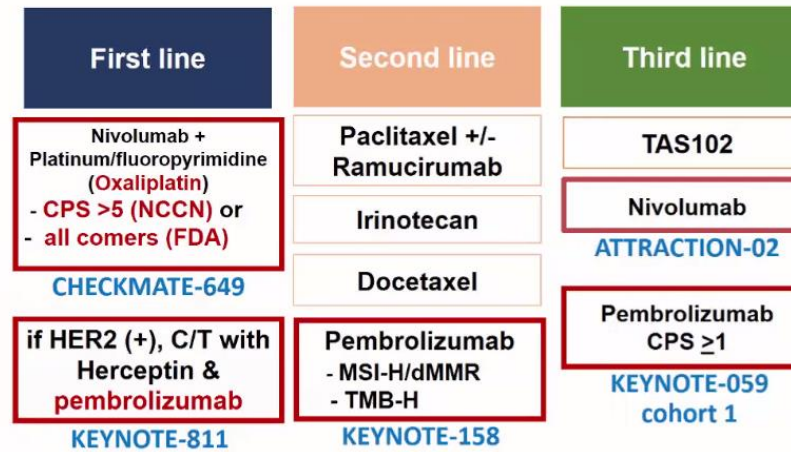


## 七、癌症藥物治療原則

- 1.對晚期食道胃腺癌和胃腺癌推薦的化療方案可以交換使用。
- 2.化療方案應該根據病患體力狀態、合併症、毒性反應和 HER2-neu 表現狀態做選擇。
- 3.對晚期腫瘤患者應用三種藥物聯合處方前，應確定患者的身體狀況良好（ECOG PS 0~1），並能夠經常進行毒性評估。
- 4.如果有證據支持毒性更低並且療效不受影響時可以優先選定 1 類方案的改良方案或使用 2A、2B 類方案。
- 5.任何方案的劑量和用藥方案若不是來自 1 類證據，則只作為一種建議，應根據具體情況進行適當修改。
- 6.允許基於是否能獲得的藥物、臨床指引中的喜好和禁忌證據改變細胞毒藥物的組合及用藥方案。
- 7.靜脈滴注 5-FU 和口服 capecitabine 可互換使用（除非明確標示）。與 5-FU 注射相比，應選靜脈持續滴注 5-FU。
- 8.Cisplatin 和 Oxaliplatin 可以根據毒性反應互換使用。
- 9.完成化療後，應該評估療效和晚期併發症。
- 10.外科手術中若為 R1 或 R2 切除病患給予腹腔內投藥 Cisplatin 100mg。

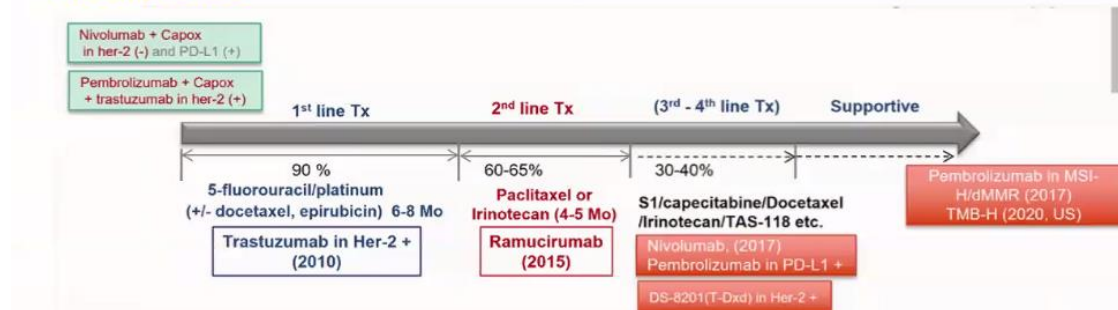


## Therapeutic Choices in Advanced GC & GEJC



## The summary of ICI Trials in GC & EGJ

Mostly HER2 -





## (一) 化學治療處方 (Principles of chemotherapy)

### Adjuvant chemotherapy

#### Cisplatin + Capecitabine

Cisplatin	60 – 70 mg/m <sup>2</sup> iv	d1
Capecitabine	1000 mg/m <sup>2</sup> po bid	14 days
Q3w x 6 cycles		

Lee J et al. Phase III trial comparing capecitabine plus cisplatin versus capecitabine plus cisplatin with concurrent capecitabine radiotherapy in completely resected gastric cancer with D2 lymph node dissection: the ARTIST trial. J Clin Oncol. 2012;30:268.(stageII-III)

#### XELOX

Oxaliplatin	130 mg/m <sup>2</sup> iv	d1
Capecitabine	1000 mg/m <sup>2</sup> po bid	14 days
Q3w x 8 cycles		

or

Oxaliplatin	65 mg/m <sup>2</sup> iv	d1, 8
Capecitabine	1000 mg/m <sup>2</sup> po bid	14 days
Q3w x 8 cycles		

Bang YJ, et al. Adjuvant capecitabine and oxaliplatin for gastric cancer after D2 gastrectomy (CLASSIC): a phase 3 open-label, randomised controlled trial. Lancet 2012;379:315.  
(stage II-IIIB)

**TS-1**

Tegafur/potassium oxonate/gimeracil	BSA < 1.25	40mg bid
	BSA 1.25 - 1.5	50mg bid
	BSA ≥ 1.5	60mg bid
4 weeks on/2 weeks off (or 2 weeks on/1 weeks off), 1 year		

Sakuramoto S, et al. Adjuvant chemotherapy for gastric cancer with S-1, an oral fluoropyrimidine. N Engl J Med. 2007;357:1810. Tegafur/gimeracil/oteracil 複方製劑(如 TS-1) (105/12/1)：(1)胃癌術後輔助性化療，用於罹患 TNM Stage II (排除 T1)、III A 或 III B 胃癌且接受過胃癌 根治性手術的成年患者，限用 1 年。  
(2)需經事前審查核准後使用。

**TS-1+Docetaxel**

TS-1	80mg/m <sup>2</sup> on Day1-14	cycle 1 (3weeks)
Docetaxel	40mg/m <sup>2</sup> on Day 1 and	TS-1 Day1-14 cycle 2-7(every 3weeks)
TS-1	80mg/m <sup>2</sup> on Day1-28	cycle ≥ 8 (3weeks)
3 weeks on/ 1 weeks off		

Yoshida, K., Kodera, Y., Kochi, M., Ichikawa, W., Kakeji, Y., Sano, T., ... & Kaji, M. (2019). Addition of Docetaxel to Oral Fluoropyrimidine Improves Efficacy in Patients With Stage III Gastric Cancer: Interim Analysis of JACCRO GC-07, a Randomized Controlled Trial. Journal of Clinical Oncology,37(15), 1296-1304.

註:適用晚期胃腺癌患者，包括胃食道接合處之腺癌

**Fluorouracil, leucovorin, oxaliplatin, and docetaxel (FLOT)**

Fluorouracil	2600 mg/m <sup>2</sup> IV continuous infusion over 24 hours on Day 1
Leucovorin	200 mg/m <sup>2</sup> IV on Day 1 Oxaliplatin 85 mg/m <sup>2</sup> IV on Day 1
Docetaxel	50 mg/m <sup>2</sup> IV on Day 1 Cycled every 14 days
4 cycles preoperative and 4 cycles postoperative	

**5-FU + LV**

5-FU	425 mg/m <sup>2</sup> /d iv	d1-5
Leucovorin	20 mg/m <sup>2</sup> /d iv	d1-5
One month later		
5-FU	400 mg/m <sup>2</sup> /d	d1-4 and last 3 days of RT
Leucovorin	20 mg/m <sup>2</sup> /d iv	d1-4 and last 3 days of RT
One month after completion of RT		
5-FU	425 mg/m <sup>2</sup> /d iv	d1-5 q4w x 2 cycles
Leucovorin	20 mg/m <sup>2</sup> /d iv	d1-5 q4w x 2 cycles

Macdonald, JS et al. Chemoradiotherapy after surgery compared with surgery alone for adenocarcinoma of the stomach or gastroesophageal junction. N Engl J Med 2001; 345:725.

## Chemotherapy for locally advanced unresectable and metastatic cancer

**Modified FOLFOX at CSMUH**

Oxaliplatin	85 mg/m <sup>2</sup> iv	d1
Leucovorin	150 - 200 mg/m <sup>2</sup> civi 46-48 hours	d1
5-FU	2400 - 3000 mg/m <sup>2</sup> civi 46-48 hours	d1
Q2w x 6 – 12 cycles		

P. C. Enzinger, et al. CALGB 80403/ECOG 1206: A randomized phase II study of three standard chemotherapy regimens (ECF, IC, FOLFOX) plus cetuximab in metastatic esophageal and GE junction cancer. J Clin Oncol 2010;28:15s.



**XELOX**

Oxaliplatin	130 mg/m <sup>2</sup> iv	d1
Capecitabine	1000 mg/m <sup>2</sup> po bid	14 days
Q3w x 4 -6 cycles		

**or**

Oxaliplatin	65 mg/m <sup>2</sup> iv	d1, 8
Capecitabine	1000 mg/m <sup>2</sup> po bid	14 days
Q3w x 4 -6 cycles		

Kim GM, et al. A randomized phase II trial of S-1-oxaliplatin versus capecitabine-oxaliplatin in advanced gastric cancer. Eur J Cancer 2012;48:518.

**or**

Oxaliplatin	85 mg/m <sup>2</sup> iv	d1,
Capecitabine	1000 mg/m <sup>2</sup> po bid	14 days
Q2w x 4 -6 cycles		

Yung-Chia Kou, et al. Modified Biweekly Oxaliplatin and Capecitabine for Advanced Gastric Cancer: A Retrospective Analysis from A Medical Center 2014;37:141-146. (stage II-IV)

**Cisplatin + 5-FU**

Cisplatin	75 - 100 mg/m <sup>2</sup> iv	d1
5-FU	750 - 1000 mg/m <sup>2</sup> /d civi	d1-4
Q4w x 3 -6 cycles		

Lorenzen S, et al. Cetuximab plus cisplatin-5-fluorouracil versus cisplatin-5-fluorouracil alone in first-line metastatic squamous cell carcinoma of the esophagus: a randomized phase II study of the Arbeitsgemeinschaft Internistische Onkologie. Ann Oncol. 2009;20:1667.

**PFL**

Cisplatin	50 mg/m <sup>2</sup> iv		d1
5-FU	2400 - 3000 mg/m <sup>2</sup> /d civi 4	6hr	d1
Leucovorin	200 mg/m <sup>2</sup> /d civi	46hr	d1
Q2w x 6-12 cycles			

Al-Batran SE et al. Phase III trial of metastatic gastroesophageal adenocarcinoma with fluorouracil, leucovorin plus either oxaliplatin or cisplatin: a study of the Arbeitsgemeinschaft Internistische Onkologie. J Clin Oncol 2008; 26:1435

**P-PFL**

Cisplatin	25-30 mg/m <sup>2</sup> iv		d1, 8, 15
5-FU	2000 - 2600 mg/m <sup>2</sup> /d civi	24hr	d1, 8, 15
Leucovorin	200 mg/m <sup>2</sup> /d civi	24hr	d1, 8, 15
Q4w x 3-6 cycles			

Hung TC et al. Weekly 24-hour infusional 5-fluorouracil as initial treatment for advanced gastric cancer with acute disseminated intravascular coagulation. Anticancer Res 2008;28:1293.

**Docetaxel +/- Cisplatin**

Cisplatin	75 mg/m <sup>2</sup> iv	d1
Docetaxel	66-75 mg/m <sup>2</sup> iv	d1
Q3w		

Roth AD et al. Docetaxel, cisplatin; and fluorouracil; docetaxel and cisplatin; and epirubicin, cisplatin, and fluorouracil as systemic treatment for advanced gastric carcinoma: a randomized phase II trial of the Swiss Group for Clinical Cancer Research. J Clin Oncol 2007; 25:3217.

Add TS1 +/- Cisplatin in stage IV irinotecan in patients with previously untreated metastatic gastric cancer: a Federation Francophone de Cancerologie Digestive Group Study--FFCD 9803. J Clin Oncol 2004; 22:4319

**Gemcitabine+Oxaliplatin+5FU+LV**

Gemcitabine	1000mg/m <sup>2</sup> iv		d1
Oxaliplatin	85mg/m <sup>2</sup> iv	4-6hrs	d2
5FU	400mg/m <sup>2</sup> iv	22hrs	d1 d2
LV	100 mg/m <sup>2</sup>		d1 d2
Q2W			

Fulfaro Fet al. Gemcitabine (GEM) plus oxaliplatin, folinic acid, and 5-fluorouracil (FOLFOX-4) in patients with advanced gastric cancer. *Cancer Chemother Pharmacol.* 2005 Dec;56(6):563-8. Epub 2005 Jul 23.

## Target therapy for locally advanced unresectable and metastatic cancer

**Trastuzumab + Chemotherapy(in Her-2 positive)**

Trastuzumab 8 mg/kg iv over 90 min first wk followed by 6 mg/kg iv over 30 min q3w

Trastuzumab 6 mg/kg iv over 90 min first wk followed by 4 mg/kg iv over 30 min q2w

Bang YJ et al. Trastuzumab in combination with chemotherapy versus chemotherapy alone for treatment of HER2-positive advanced gastric or gastro-oesophageal junction cancer (ToGA): a phase 3, open-label, randomised controlled trial. *Lancet* 2010;376:687.



## Gastric cancer stage IV dependent on prior therapy and patient performance status

### Irinotecan

Irinotecan	150-180 mg/m <sup>2</sup> iv	d1
Q2w		

Hironaka S et al. Randomized, open label, phase III study comparing irinotecan with paclitaxel in patients with advanced gastric cancer without severe peritoneal metastasis after failure of prior combination chemotherapy using fluoropyrimidine plus platinum: WJOG 4007 trial, J Clin Oncol 2013;31: 4438-4444.

### Paclitaxel

Paclitaxel	60-80 mg/m <sup>2</sup> iv	d1, 8, 15
Q4w		

Ilson DH et al. Paclitaxel given by a weekly 1 h infusion in advanced esophageal cancer. Ann Oncol 2007;18:898.

### Ramucirumab +/- Paclitaxel

Ramucirumab	8 mg/kg iv	d1, 15
Paclitaxel	60-80 mg/m <sup>2</sup> iv	d1, 8, 15
Q4w		

White H et al. Ramucirumab plus paclitaxel versus placebo plus paclitaxel in patients with previously treated advanced gastric or gastro-esophageal junction adenocarcinoma: a double-blind, randomised phase 3 trial. Lancet Oncol 2014; 15:1224-1235.

### Docetaxel

Docetaxel	66- 75 mg/m <sup>2</sup> iv	d1
Q3w		

**Irinotecan + Cisplatin**

Irinotecan	65 mg/m <sup>2</sup> iv	d1, 8
Cisplatin	25-30 mg/m <sup>2</sup>	d1, 8
Q3w		

**Modified FOLFIRI at CSMUH**

Irinotecan	150-180 mg/m <sup>2</sup> iv	d1
Leucovorin	150 - 200 mg/m <sup>2</sup> civi 46-48 hours	d1
5-FU	2400 - 3000 mg/m <sup>2</sup> civi 46-48 hours	d1
Q2w		

**HIPEC(Hyperthermic Intraperitoneal Chemotherapy)**

Cisplatin 120 mg+Mitomycin 30mg each in 6000 ml of normal saline at 40-43°C for 60-90 min.
Peritoneal carcinomatosis from gastric cancer

Olivier Glehen et al. Peritoneal Carcinomatosis from Gastric Cancer:A Multi-Institutional Study of 159 Patients Treated by Cytoreductive Surgery Combined with Perioperative Intraperitoneal Chemotherapy (2010) 17:2370–2377

Xiao-Jun Yang et al. Cytoreductive Surgery and Hyperthermic Intraperitoneal Chemotherapy Improves Survival of Patients with Peritoneal Carcinomatosis from Gastric Cancer: Final Results of a Phase III Randomized Clinical Trial (2011) 18:1575–1581



### 第三線化療藥物

藥名	給藥途徑	建議劑量	適用條件	健保
Lonsurf (TAS-102)	口服	最大劑量不可超過 82mg/day	用於治療先前曾接受兩種 (含)以上治療(包括含 fluoropyrimidine-、platinum-、taxane-或 irinotecan 為基礎的化學療法，以及 HER2/neu 標靶治療[如果適合]) 的轉移性胃腺癌或胃食道接合處腺癌病人。	給付

備註:每天給藥兩次，在第 1~5 天與第 8~12 天，每 28 天為一個療程。

### (二)標靶藥物治療

藥名	給藥途徑	建議劑量	適用條件	健保
Trastuzumab (Herceptin)	靜脈注射	4mg/Kg	轉移性胃癌(限 IV 劑型) trastuzumab 合併 capecitabine (或 5-fluorouracil)及 cisplatin 適用於未曾接受過化學治療之 HER2 過度表現(IHC3+或 FISH+)轉移性胃腺癌(或胃食道接合處腺癌)的治療。	給付



### (三) 免疫藥物治療

藥名	給藥途徑	建議劑量	適用條件	健保
Pembrolizumab (Keytruda)	靜脈注射	200 mg/次/day 3週打一次	胃癌治療患有復發性局部晚期或轉移性胃腺癌或胃食道接合部腺癌，經確效性試驗檢測出腫瘤有 PD-L1 表現(綜合陽性分數 CPS $\geq$ 1)，且先前曾在使用兩種(含)以上之療法(包括含有 fluoropyrimidine 及含鉑化學療法，以及 HER2/neu 標靶療法[如果適合])治療時或治療後出現疾病惡化現象的病人。	給付
Nivolumab	靜脈注射	3 mg/kg 2 週打一次	無法切除的晚期或復發性胃癌:用於治療先前經兩種或兩種以上化學治療的晚期或復發性胃癌或胃食道癌-TFDA	給付



## 八、放射線治療原則

### Radiotherapy with external beam

1. Dose: 45-50Gy (1.8Gy per fraction, per day)
2. Treatment field:
3. Proximal one-third/Cardia/GE junction
  - A. Proximal: gastric lesion, 3~5 cm margin of distal esophagus, medial left hemidiaphragm and adjacent pancreatic body.
  - B. Nodal area: adjacent paraesophageal, perigastric, suprapancreatic, and celiac lymph nodes.
4. Middle one third/Body
  - A. Proximal: gastric lesion, pancreatic body.
  - B. Nodal area: adjacent perigastric, suprapancreatic, celiac, splenic hilar, porta hepatic and pancreatoduodenal lymph nodes.
5. Third one third/Antrum/Pylorus
  - A. Proximal: gastric lesion and head of pancreas. If gross lesion extent to gastroduodenal junction, 3~5 cm margin of duodenal stump.
  - B. Nodal area: Perigastric, suprapancreatic, celiac, porta hepatic and pancreatoduodenal lymph nodes.





## 九、安寧緩和照護原則

若預期疾病難以治癒時，病人存活期小於 6 個月便適合安寧療護(Pomeranz & Brustman, 2005；Waldrop & Rinfrette, 2009)。若藉由症狀、檢驗數據、及確切的腫瘤診斷，證實臨床上該惡性腫瘤已經廣泛侵犯、或進展快速；功能分數(Palliative Performance Scale)低於 70%；拒絕進一步腫瘤治癒性治療，或者在治療之下仍持續惡化者，即可轉介緩和醫療團隊（彭等，2006）。

## 十、完治率定義

癌別	分期	治療方式	完治率定義
胃癌	原位癌、第 I 期	OP(包含 ESD、EMR)	後續追蹤腹部電腦斷層，報告顯示無轉移或復發，即可算首次治療完成
	第 II 期	OP+輔助性化療	手術+輔助性化療滿 6 個月，後續追蹤腹部電腦斷層，報告顯示無轉移或復發，即可算首次治療完成(治療中轉安寧，算完成治療)
	第 III 期	OP+輔助性化療	手術+輔助性化療滿 3 個月，後續追蹤腹部電腦斷層，報告顯示無轉移或復發，即可算首次治療完成(治療中轉安寧，算完成治療)
	第 IV 期	Palliative OP	手術完成，即可算首次完成治療
Palliative 化療		療程滿 3 個月就可算完成治療(治療中轉安寧，算完成治療)	
Palliative 化療+免疫			



## 十一、參考文獻

1. 國家衛生研究院胃癌臨床診療指引,台灣癌症臨床研究合作組織.
2. NCCN Clinical Practice Guidelines in Oncology (NCCN Guidelines™) Esophageal Cancers and Esophagogastric Junction (Excluding the proximal 5cm of the stomach) Version 3.2020
3. 彭仁奎、邱泰源、陳慶餘 (2006) , 老年緩和醫療簡介, 安寧療護雜誌 11(3) , 273-284
4. Bedenne L et al. Chemoradiation followed by surgery compared with chemoradiation alone in squamous cancer of the esophagus: FFCO 9102. J Clin Oncol 2007; 25:1160.
5. Hershkovic A et al. Combined chemotherapy and radiotherapy compared with radiotherapy alone in patients with cancer of the esophagus. N Engl J Med 1992; 326:1593.
6. Lee J et al. Phase III trial comparing capecitabine plus cisplatin versus capecitabine plus cisplatin with concurrent capecitabine radiotherapy in completely resected gastric cancer with D2 lymph node dissection: the ARTIST trial. J Clin Oncol. 2012;30:268.
7. Bang YJ, et al. Adjuvant capecitabine and oxaliplatin for gastric cancer after D2 gastrectomy (CLASSIC): a phase 3 open-label, randomised controlled trial. Lancet 2012;379:315.
8. Sakuramoto S, et al. Adjuvant chemotherapy for gastric cancer with S-1, an oral fluoropyrimidine. N Engl J Med. 2007;357:1810.
9. Ychou M et al. Perioperative chemotherapy compared with surgery alone for resectable gastroesophageal adenocarcinoma: an FNCLCC and FFCO multicenter phase III trial. J Clin Oncol 2011;29:1715
10. Macdonald, JS et al. Chemoradiotherapy after surgery compared with surgery alone for adenocarcinoma of the stomach or gastroesophageal junction. N Engl J Med 2001; 345:725.
11. P. C. Enzinger, et al. CALGB 80403/ECOG 1206: A randomized phase II study of three standard chemotherapy regimens (ECF, IC, FOLFOX) plus cetuximab in metastatic esophageal and GE junction cancer. J Clin Oncol 2010;28:15s.
12. Kim GM, et al. A randomized phase II trial of S-1-oxaliplatin versus capecitabine-oxaliplatin in advanced gastric cancer. Eur J Cancer 2012;48:518.
13. Lorenzen S, et al. Cetuximab plus cisplatin-5-fluorouracil versus cisplatin-5-fluorouracil alone in first-line metastatic squamous cell carcinoma of the esophagus: a randomized phase II study of the Arbeitsgemeinschaft Internistische Onkologie. Ann Oncol. 2009;20:1667.



14. Al-Batran SE et al. Phase III trial of metastatic gastroesophageal adenocarcinoma with fluorouracil, leucovorin plus either oxaliplatin or cisplatin: a study of the Arbeitsgemeinschaft Internistische Onkologie. *J Clin Oncol* 2008; 26:1435
15. Hung TC et al. Weekly 24-hour infusional 5-fluorouracil as initial treatment for advanced gastric cancer with acute disseminated intravascular coagulation. *Anticancer Res* 2008;28:1293.
16. Cunningham D et al. Capecitabine and oxaliplatin for advanced esophagogastric cancer. *N Eng J Med* 2008; 358:36.
17. Cunningham D et al. Capecitabine and oxaliplatin for advanced esophagogastric cancer. *N Eng J Med* 2008; 358:36.
18. Ajani JA et al. Clinical benefit with docetaxel plus fluorouracil and cisplatin compared with cisplatin and fluorouracil in a phase III trial of advanced gastric or gastroesophageal cancer adenocarcinoma: The V-325 Study Group. *J Clin Oncol* 2007; 25:3205
19. Al-Batran SE et al. Biweekly fluorouracil, leucovorin, oxaliplatin, and docetaxel (FLOT) for patients with metastatic adenocarcinoma of the stomach or esophagogastric junction: a phase II trial of the Arbeitsgemeinschaft Internistische Onkologie. *Ann Oncol* 2008;19:1882.
20. Albertsson M et al. Phase II studies on docetaxel alone every third week, or weekly in combination with gemcitabine in patients with primary locally advanced, metastatic, or recurrent esophageal cancer. *Med Oncol* 2007;24:407.
21. Roth AD et al. Docetaxel, cisplatin; and fluorouracil; docetaxel and cisplatin; and epirubicin, cisplatin, and fluorouracil as systemic treatment for advanced gastric carcinoma: a randomized phase II trial of the Swiss Group for Clinical Cancer Research. *J Clin Oncol* 2007; 25:3217.
22. Ilson DH et al. Paclitaxel given by a weekly 1-h infusion in advanced esophageal cancer. *Ann Oncol* 2007;18:898.
23. Kornek, GV et al. Effective combination chemotherapy with paclitaxel and cisplatin with or without human granulocyte colony-stimulating factor and/or erythropoietin in patients with advanced gastric cancer. *Br J Cancer* 2002; 86:1858.
24. Fuchs CS et al. Phase III comparison of two irinotecan dosing regimens in second-line therapy of metastatic colorectal cancer. *J Clin Oncol* 2003;21:807.
25. Ajani, JA et al. CPT-11 plus cisplatin in patients with advanced, untreated gastric or gastroesophageal junction carcinoma: results of a phase II study. *Cancer* 2002; 94:641.
26. Bouche, O et al. Randomized multicenter phase II trial of a biweekly regimen of fluorouracil and leucovorin (LV5FU2), LV5FU2 plus cisplatin, or LV5FU2 plus irinotecan in patients with previously untreated metastatic gastric cancer: a Federation Francophone de Cancerologie Digestive Group Study--FFCD 9803. *J Clin Oncol* 2004; 22:4319
27. Bang YJ et al. Trastuzumab in combination with chemotherapy versus chemotherapy alone for treatment of HER2-positive advanced gastric or



- gastro-oesophageal junction cancer (ToGA): a phase 3, open-label, randomised controlled trial. *Lancet* 2010;376:687.
28. Yung-Chia Kou, et al. Modified Biweekly Oxaliplatin and Capecitabine for Advanced Gastric Cancer: A Retrospective Analysis from A Medical Center 2014;37:141-146.
29. Mahul B. Amin et al. *AJCC Cancer Staging Manual* 8<sup>th</sup>. 2017. Springer p.203-220
30. Kang YK et al., Nivolumab in patients with advanced gastric or gastro-oesophageal junction cancer refractory to, or intolerant of, at least two previous chemotherapy regimens (ONO-4538-12, ATTRACTION-2): a randomised, double-blind, placebo-controlled, phase 3 trial. *Lancet* 2017;390:2461-2471 2.
31. Yoshida, K., Kodera, Y., Kochi, M., Ichikawa, W., Kakeji, Y., Sano, T., ... & Kaji, M. (2019). Addition of Docetaxel to Oral Fluoropyrimidine Improves Efficacy in Patients With Stage III Gastric Cancer: Interim Analysis of JACCRO GC-07, a Randomized Controlled Trial. *Journal of Clinical Oncology*, 37(15), 1296-1304.
32. Al-Batran, S. E., Homann, N., Pauligk, C., Goetze, T. O., Meiler, J., Kasper, S., ... & Lindig, U. (2019). Perioperative chemotherapy with fluorouracil plus leucovorin, oxaliplatin, and docetaxel versus fluorouracil or capecitabine plus cisplatin and epirubicin for locally advanced, resectable gastric or gastro-oesophageal junction adenocarcinoma (FLOT4): a randomised, phase 2/3 trial. *The Lancet*, 393(10184), 1948-1957.
33. Shitara, Kohei, et al. "Trifluridine/tipiracil versus placebo in patients with heavily pretreated metastatic gastric cancer (TAGS): a randomised, double-blind, placebo-controlled, phase 3 trial." *The Lancet Oncology* 19.11 (2018): 1437-1448.